

# Impact of acacia arabica topical gel on skin wound healing: An experimental study

Eman Abdullah<sup>1</sup>, Sara Taha<sup>1</sup>, Noor Sulaiman<sup>2</sup>, Muna Ahmed<sup>3</sup>

<sup>1</sup> College of Pharmacy, Mosul University, Mosul, Iraq

<sup>2</sup> College of Dentistry, Mosul University, Mosul, Iraq

<sup>3</sup> College of Medicine, Mosul University, Mosul, Iraq

Corresponding author: Noor Sulaiman (noorabdullah@uomosul.edu.iq)

Received 5 August 2021 ♦ Accepted 19 October 2021 ♦ Published 11 January 2022

**Citation:** Abdullah E, Taha S, Sulaiman N, Ahmed M (2022) Impact of acacia arabica topical gel on skin wound healing: An experimental study. Pharmacia 69(1): 77–83. <https://doi.org/10.3897/pharmacia.69.e72595>

## Abstract

**Aim of the study:** To estimate the influence of *Acacia Arabica* gel abstract on skin wound healing. **Material and method:** 28male adult rabbits were included, 2 incisions of 1cm length were made on the skin of the rabbit's back, one is treated by acacia gel while another left for normal healing, histopathological examination was done at 24h, 3, 7 and 14 days intervals. **Results:** The inflammatory reactions showed no significant results for both the control group and the study group during the study intervals. Granulation tissue in the control group was absent after 24h but increased to become profound after 7 days then become moderate, while the study group showed scanty granulation tissue from the first day and increased through study intervals. Re-epithelialization mean scores in the study group were higher than control one. **Conclusions:** *Acacia arabica* has the efficacy of hastening the wound healing process.

## Keywords

*Acacia arabica* extract, *Acacia* gel efficacy, *Acacia* topical gel, wound healing

## Introduction

Wound healing is a vibrant physiological chain that comprises a sequence of stages and intervenes by the collaboration of a multifaceted cascade of cellular and biochemical activities, resulting in renovation of structural and functional entirety with the recovery of injured tissues strength. If wound healing phases do not continue in this way, healing may unsuitably progress to a chronic wound (Thakur et al. 2011). Wound healing stages start with hemostasis in which blood clots cover the whole wound. The inflammatory phase comprises the production of inflammatory infiltrate fluids, fibrin deposition, and immigration of monocytes, neutrophil polymorphs, and lymphocytes. Then is a proliferative phase in which

new blood vessels formation (angiogenesis) with ground substances occurs, precipitation of collagen, granulation tissue creation, epithelialization, contraction of a wound, and lastly remodeling (Midwood et al. 2004). When collagen connects all damaged surfaces definitely, completion of healing occurs (Govindarajan et al. 2007).

Use of natural materials that have medicinal features can hasten this physiological procedure. Many researches about wound healing characteristics of natural crops with anti-inflammatory, antibacterial, pro-collagen synthesis, and antioxidant activities have been steered, bioactive phytochemical constituents may play important role in these medicinal features, these include several chemical collections like alkaloids, essential oils, flavonoids, tannins, terpenoids, saponins, and phenolic

compounds (Thakur et al. 2011). Each of these phytochemical has a precise effect on the wound healing process such as saponins can increase pro-collagen synthesis, whereas flavonoids and tannins have antiseptic and antibacterial activities (Thakur et al. 2011). They are imbibed so easily by the superficial layers of the skin. So they have an essential function in healing the wound and are used in the new synthetic materials formation (Ibrahim et al. 2018). Free radical scavenging enzymes (FRSE) can be inactivated and reactive oxygen species (ROS) removed which are damaging to wound healing as it has toxic properties on tissue (Aliyev et al. 2004). Tissues reservation from oxidative damage and then high healing ratio of the wound can be achieved by topical application of natural medicinal materials with free radical scavenging activities (BENT 2008).

The herbs used as medicine are increasingly distributed throughout the world, due to their availability, natural source and have high healing properties with little or even no side effects (Malviya et al. 2011). Particular plants used in outmoded medicine perform as a therapeutic mediator source by having many prospective features with antimicrobial action (Takahashi et al. 2003). One of these medicinal plants is Acacia. Acacia gum has been widely deliberated and commercially used because of several properties as lower viscosity even at a higher concentration, higher water solubility, and emulsion property (Bhushette and Annapure 2017). Acacia plant has several names such as *Acacia arabica*, *Acacia nilotica*, Babul, Kikar, Babhul – Hindi and Napalese, Sanskrit, Babul Tree, Huanlong Kyain, and others (Ali et al. 2012).

Gum Arabic is a normal separated-string hydrocolloid with several functions, highly balanced or a little acidic, arabinogalactan-protein components include magnesium, calcium, and potassium (Renard et al. 2006). The Joint Expert Committee for Food Additives (JECFA) describes Gum Arabic as a dehydrated extract produced from the stalk and branches of *Acacia* trees (Phillips and Williams 2001). Babul botanical name is *Acacia arabica* existing wildly in the Indian subcontinent and hot Africa. Phloem Leaves and the gum of the tree all have medicinal abilities, such as antihistaminic, antibacterial, astringent, anti-inflammatory, and hemostatic chattels (Tangade et al. 2012).

In India, *Acacia nilotica* leaves are effective in conjunctivitis treatment; Gum of *Acacia nilotica* eliminates any skin irritation and smoothing pharynx membranes inflammation, gastrointestinal and genito-urinary tracts. A mixture of sea salt with a decoction of the *Acacia nilotica* bark can be used as a gargle in tonsillitis treatment (Rajvaidhya et al. 2012). Acacia is considered as a basis of polyphenols (Rodge et al. 2012). The phytochemical include several groups which are alkaloids, essential oils, volatile, resins, oleosins, phenols and phenolic glycoside, terpenes, steroids, and tannins (Banso 2009). Also, various parts of this plant are very rich in tannins (ellagic acid, gallic acid, and tannic acid), vitamin-C (ascorbic acid), stearic acid, crude fiber, carotene, crude protein, calcium, Arabin, magnesium, and

selenium (Meena et al. 2006). So *Acacia nilotica* can produce nutrients and healing ingredients to prevent, decrease or manage many disorders (Rodge et al. 2012).

We hypothesized that topical application of *Acacia* plant extract as a gel formula with a specific concentration can accelerate skin wound healing. This study aims to evaluate the effectiveness of *Acacia Arabica* topical gel with 5% concentration in accelerating wound healing of the skin in rabbits.

## Material and method

### Preparation of acacia gel

The gel was formulated using Carbopol 934 as a gelling agent in 0.5 % concentration. Acacia in 5% concentration was used. This concentration was chosen considering the concentration of acacia used in some marketed products.

The required weight of acacia powder was dispersed in distilled water (D.W.) and stirred using a magnetic stirrer until complete dispersion was achieved. Required weight of Carbopol 934 was then added. The resultant mixture was left for 24 hours to ensure complete swelling of Carbopol. The next step aimed to complete the volume of the mixture with D.W. and ensure uniform distribution of the two components throughout the dispersion. Triethanolamine (TEA) was used as a neutralizing agent to convert Carbopol into gel state by increasing the pH of the mixture. TEA was added wisely drop by drop using a micropipette until the gel is formed. The prepared formulas were stored refrigerated in tightly closed sterile containers.

### Animals

28 male domestic rabbits were used, aged 7–8 months, each  $2 \pm 0.5$  kg in weight in this study. They were retained and nourished in natural food (greens, corn, and cereals) and water independently, in an area with a normal light cycle and fixed temperature ( $24 \pm 2$  °C). The Scientific, Ethical, and Animal Welfare Committee of the College of Pharmacy, University of Mosul, approved the protocol for this study. Preceding to the treatment ethical code number. UM.VET.2021.002 on 27/6/2021, each rabbit was evaluated for 1 week to check the overall wellbeing and certify that no transmittable illness was present.

### Surgical procedure

The rabbits were erratically separated into four equivalent sets in accordance with the healing time (1, 3, 7 and 14 days), every set comprising 7 animals. Every rabbit was narcotized with 40 mg/kg ketamine injection (Paknejad et al. 2017) intramuscularly in the leg muscle, blended with xylazine 4 mg/kg body weight (Kilic 2004) auxiliary sedation was given if required, throughout the operation. After 5 minutes, comprehensive anesthesia had been

gotten, Local anesthesia was administered in the operated site (lidocaine and epinephrine of 2% and 1:80,000 concentration respectively 1 ml in size, New Stetic com. Colombia), 2 linear incisions of (1cm (centimeter) length and 0.5 cm depth) was performed on the back of every rabbit, one on the left and other on the right side of the back. One incision was left for normal healing, whereas another was medicated with 5% acacia gel once daily for about 14 days (Figure 1).

Histopathological samples were gathered from incisions of 7 rabbit's back of every set at 1, 3, 7, and 14 days following scarifying. Then, newly formed 10% formalin was used to conserved biopsies for 48 hours. After fixation, the samples were dried out over ascending ordered successions of xylene in addition to ethanol before being submerged in paraffin wax. 4–5  $\mu$ m width pieces were cut and stained by hematoxylin and eosin. Two skilled pathologists using a double-blind checking manner investigate the slides using a binocular light microscope (Optika, Ponteranica (BG) – Italy). The samples were estimated under a 4  $\times$  and 10  $\times$  magnification low-power field (LPF) to assess the wound healing. The pictures of the histologic units of (control and study) groups were captivated with a digital camera 8 megapixels (Aiptek, Germany) joined to the same microscope and kept on a private computer.

## Histopathological examination and scoring system

Following sacrifice, histopathological samples of all incisions of rabbits were taken at the various interval of (1, 3, 7, and 14 days), Histopathological recording of inflammation and renovation was done following the system proposed by (Gupta and Kumar 2015; Lopez-Jornet et al. 2009). This system includes inflammation, Granulation tissue, and re-epithelialization (Figures 2–8).

**Inflammatory infiltrate scoring:** (Score 1 plenty, Score 2 moderate, Score 3 a few)

**Amount of granulation tissue:** (Score 1 profound, Score 2 Moderate, Score 3 scanty, Score 4 absent)

## Re-epithelialization scoring

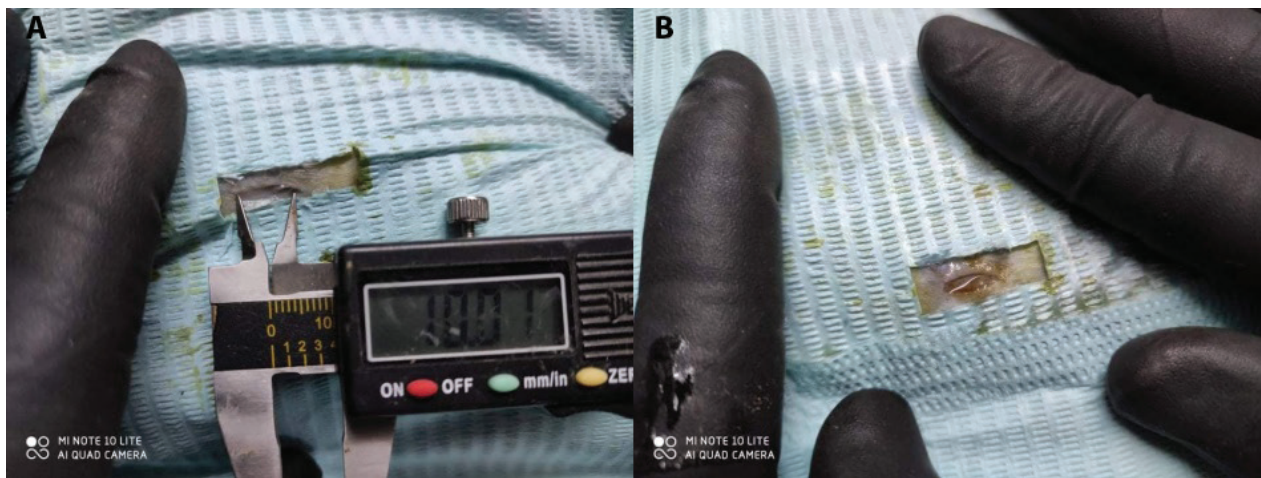
Score 0: Re epithelialization at the edge of wound

Score 1: Re epithelialization covering less than half of the wound

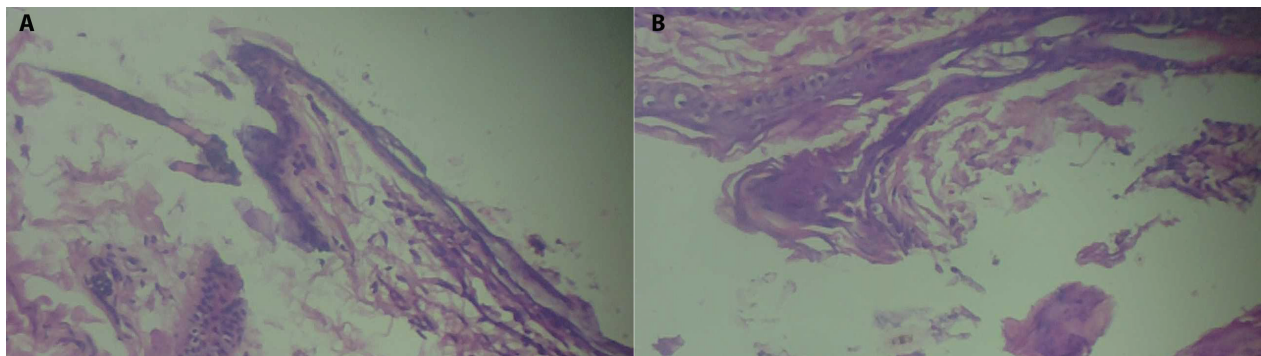
Score 2: Re epithelialization covering more than half of wound

Score 3: Re epithelialization covering the entire wound, irregular thickness.

Score 4: Re epithelialization covering the entire wound, normal thickness.

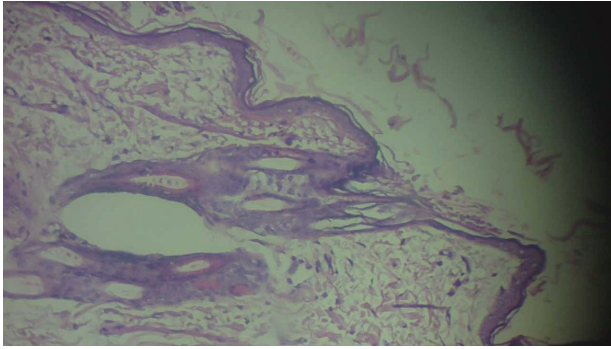


**Figure 1.** A 1 cm incision on skin B 5% Acacia gel on the incision.

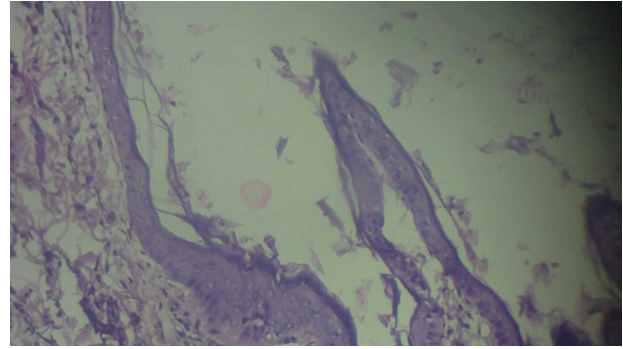


**Figure 2.** Skin specimen first day A- control group, B- 5% Acacia gel shows epithelialization (10 $\times$  power with hematoxylin and eosin stain).

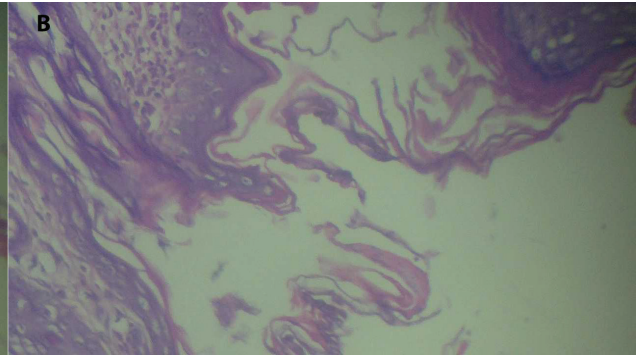
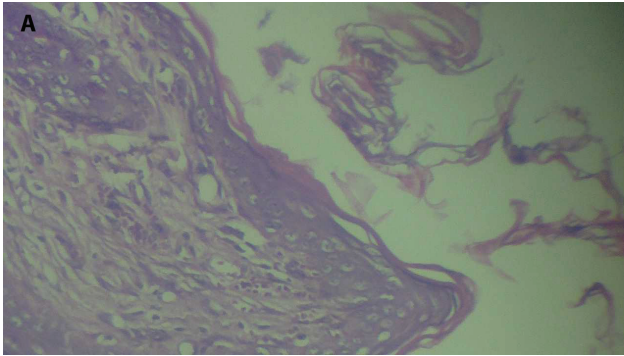




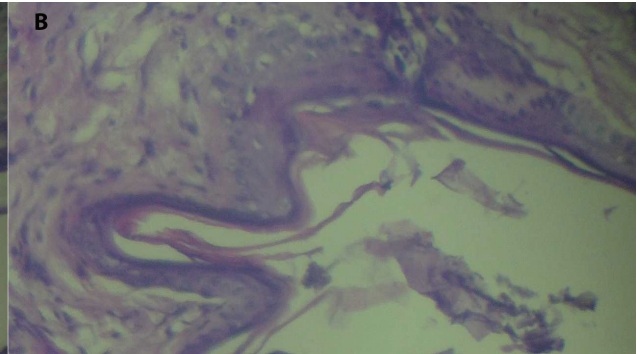
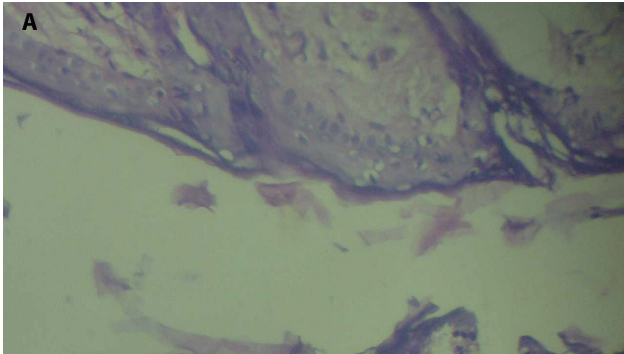
**Figure 3.** Skin specimen control group at 3days, incision with granulation tissue present (10× power with hematoxylin and eosin stain).



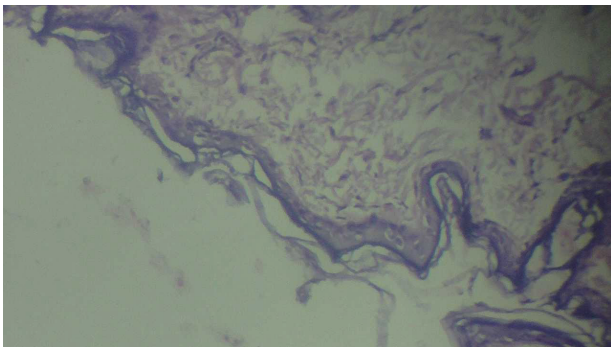
**Figure 4.** Skin specimen 5% acacia gel group at 3 days, shows epithelialization covering the complete incision.



**Figure 5.** Skin specimen control group at 7days, epithelialization bridge entire incision but uneven. A- with 40× Magnification power, B- 10× Magnification power.



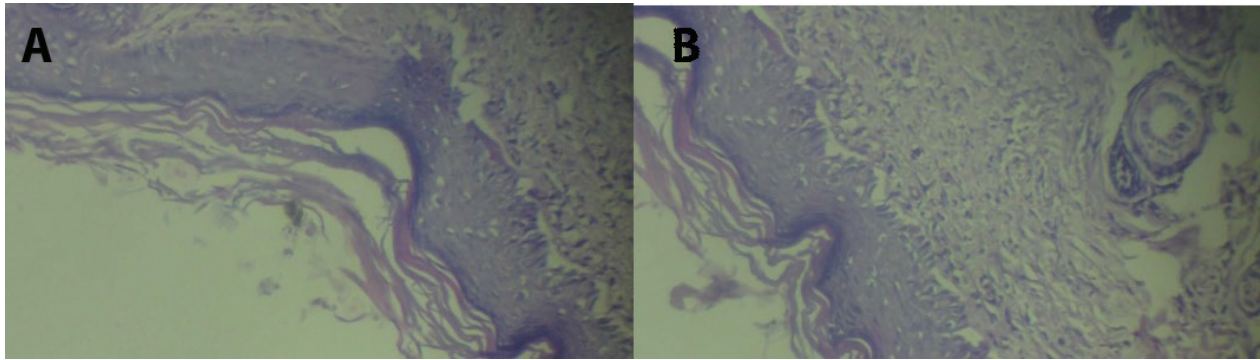
**Figure 6.** Skin 5% acacia gel group at 7days, good epithelialization whole incision but uneven, A- 40× Magnification power, B- 10× Magnification.



**Figure 7.** Skin control group at 14 days, mild epithelialization of full incision without keratin 40x power of magnification.

### Data analysis:

Expression of all scores appears as the mean and standard deviation of all parameters. Statistical analysis was done by SPSS program version 25, and the variations between groups were examined by using the Mann-Whitney test. P-value equivalent to or less than 0.05 was detected as statistically significant.



**Figure 8.** Skin 5% acacia gel group at 14 days, good epithelialization with keratinization 10× power of magnification.

## Results

The inflammatory reaction at first 24 hours in the control group was 3 while in the study group was 2.7 which is less than the control group after 3 days both groups show the same score of inflammatory reaction which was 3 and still so to the 7 days and day 14 (Table 1, Figure 9).

About granulation tissue, on the first day, the study group was 3 while the control was 4 after 72 hours granulation tissue decreased in the control group which was 3 while the study was still 3. At one-week granulation tissue score in the study group was 2 while the control was 1.28 and after 14 days study group was still 2 while the control increase to reach 3 (Table 2, Figure 10).

At 24 hours both groups show a score of 0, after 3 days the re-epithelialization for the control group was 1 while the study group was 3 then after 7 days both groups again shows the same score which was 3, at 14 days the control group was still the same score 3 while for the study group the re-epithelialization score was 4 (Table 3, Figure 11).

**Table 1.** Inflammatory scoring.

Days	Control	5% Gel	P- value
1	3±0	2.7±0.48	1.00
3	3±0	3±0	
7	3±0	3±0	
14	3±0	3±0	

Data appeared as Mean ± Standard deviation. P-Value ≤ 0.05 was significant

**Table 2.** Granulation tissue formation.

Days	Control	5% Gel	P- value
1	4±0	3±0	
3	3±0	3±0	
7	1.28±0.48	2±0	
14	3±0	2±0	

Data appeared as Mean ± Standard deviation. P-Value ≤ 0.05 was significant

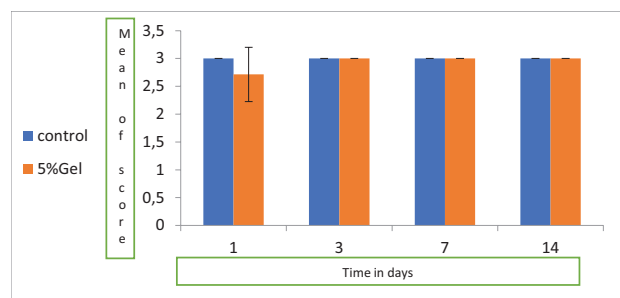
**Table 3.** Re-epithelialization scoring of skin.

Days	Control	5% Gel	P- value
1	0±0	0±0	
3	1±0	3±0	
7	3±0	3±0	
14	3±0	4±0	

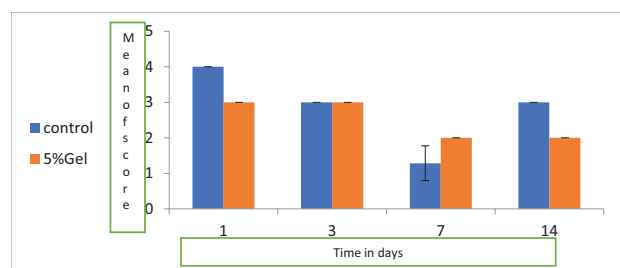
Data appeared as Mean ± Standard deviation. P-Value ≤ 0.05 was significant

## Discussion

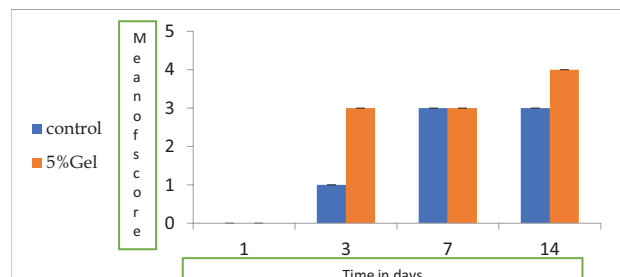
The rabbit paradigm can be a beneficial inspection implement for trying innovative treatments. Rabbit skin is absolutely different from human skin. The healing probability is extremely rapid, with quick wound shrinkage and a great proliferation (LEMO et al. 2010). Healing of wound is a process affected by multiple factors, diminishing of this procedure related to insufficiency or nonexistence of conjunction between many crucial influences. Most of



**Figure 9.** Inflammatory reaction during 14 days.



**Figure 10.** Granulation tissue reaction.



**Figure 11.** Re-epithelialization score.

operation injuries are sutured directly after completion of the operation. While some wounds let to recover by secondary intention due to infection or contamination, they were conventionally packed in theater by a simple dressing, such as ribbon gauze saturated in antiseptic or saline (Fries et al. 2005; Pukki et al. 2010).

*Acacia Arabica* can be used as a homeostatic and antibacterial factor to aid in hastening wound healing. The biopolymers in *Acacia Arabica* can be potential ingredients that can be used for dressing the wound. This can assist in the quicker restoration of the damaged tissues (Bhatnagar et al. 2013).

5% *Acacia Arabica* extractor was used in a gel form in this study, placed on the skin incision and matched to control groups to identify the action and efficacy of acacia in wound healing. The inflammatory reaction at first day increased in the study group than the control group, while for the rest of the time (3,7 and 14 ) days the inflammatory score is similar for both two groups, and this usually contrary to other studies which stated that “In the cyclooxygenase test, nicotine possessed activity with IC50 values of 28 and 210µM against COX-1 and COX-2, respectively” (Rajvaidhya et al. 2012), also other studies stated that “The aqueous extracts of *Acacia nilotica* and *Hibiscus sabdariffa* were tested for anti-inflammatory, analgesic and antipyretic activities in animal models. *Acacia nilotica* extract had an inhibitory effect on carrageenan-induced paw edema and yeast-induced pyrexia in rats. It also produced a significant increase in the hot plate reaction time in mice” (Dafallah And al-Mustafa 1996). This contrasting result may be related to technical errors in our study like the method of application of the gel to the wound area, which causes irritation of the skin and increases inflammation.

About granulation tissue, at first day there is a scanty amount of granulation tissue in the acacia group while in the control group it is absent, after 3 days the granulation tissue still the same for the study group but became scanty in the control group, after 7 days both groups show increased score of granulation tissue formation especially control group in which profound granulation tissue appears while a moderate amount of tissue formed in the study group, at 14 days later the granulations decreased in the control group from the profound amount to moderate while still moderate for the study group, in general, there is an increase in the granulation tissue formation in study groups more than a control group. As there is no preceding evidence or studies associated with this section so we relied on a study that identifies the therapeutic potential of *Acacia Leucophloea* extract on wound healing when applied as topical gel showed increased in production and precipitation of matrix proteins in the granulation tissues and collagen formation, so increased in granulation tissue formation in study group (Suriyamoorthy et al. 2012).

The phytochemical as tannins, phenols, alkaloids, and flavonoids are an essential replication of the therapeutic

effects of the acacia plant. Extract phytochemistry of the plant showed the existence of carbohydrates, phytoosterols, glycosides, saponins, phenolic complexes, and flavonoids as main ingredients; the value of these component is well recognized for antimicrobial activities. These verdicts are in coincide with previous discoveries of phytoconstituents of other many excerpts of *Acacia nilotica*, namely, aqueous extract, methanolic, and ethanolic extracts (Sharma et al. 2014). For re-epithelialization, all the slides of the *Acacia Arabica* group show early epithelialization from the third day, which was covering the whole wound but is uneven, while the control groups show epithelialization wrapping less than half of the wound. At one week the re-epithelialization in control groups cover the entire wound but irregularly this result seen from the third day for the study group, after 14 days all study group shows epithelium cover entire wound and become regular normal thickness and return to normal skin condition whereas in control groups epithelium still present with irregular thickness, so there is a rapid and short period of epithelialization of wounds in which epithelium was regular and similar to normal skin before incision in *Acacia* groups and this agreement with another study revealed: “Based on the increased epithelisation, angiogenesis and collagen fibers formation observed in the treated groups, it can be inferred that *A. nilotica* pod extract enhances wound healing via angiogenesis, collagen deposition epithelisation and wound contraction” (KANKARA et al. 2017).

## Conclusion

Topical application of 5% *Acacia Arabica* plant extract in gel form has high efficacy in the acceleration of healing of wound in skin rabbit obviously. And it has shown no any local or systemic side effects on the wound and the animal, respectively.

## Conflict of interest

The authors have declared that no competing interests exist.

## Funding

The authors have no funding to report.

## Acknowledgment

All authors are grateful for the members of the College of Pharmacy and Dentistry College of Mosul University in Iraq.



## References

- Ali A, Akhtar N, Ali Khan B, Shoaib Khan M, Rasul A, UZ-Zaman Sh, Khalid N, Waseem Kh, Mahmood T and Ali L (2012) *Acacia nilotica*: A plant of multipurpose medicinal uses, Journal of Medicinal Plants Research 6(9): 1492–1496. Academic Journals. <https://doi.org/10.5897/JMPR11.1275>
- Aliyev E, Sakallioğlu U, Eren Z, Açıkgöz G (2004) The effect of polylactide membranes on the levels of reactive oxygen species in periodontal flaps during wound healing. Biomaterials 25(19): 4633–7. <https://doi.org/10.1016/j.biomaterials.2003.12.004>
- Kumar BM, Vijayakumar R, Govindarajan P (2007) Pushpangadan, Ethnopharmacological approaches to wound healing – Exploring medicinal plants of India. Journal of Ethnopharmacology 114(2): 103–113. <https://doi.org/10.1016/j.jep.2007.08.010>
- Banso A (2009) Phytochemical and antibacterial investigation of bark extracts of *Acacia nilotica*. Journal of Medicinal Plants Research 3(2): 082–085.
- Bent S (2008) Herbal Medicine in the United States: Review of Efficacy, Safety, and Regulation. Journal of General Internal Medicine 23: 854–859. <https://doi.org/10.1007/s11606-008-0632-y>
- Bhatnagar M, Parwani L, Sharma V, Ganguli J, Bhatnagar A (2013) Hemostatic, antibacterial biopolymers from *Acacia arabica* (Lam.) Willd. and *Moringa oleifera* (Lam.) as potential wound dressing materials. Indian J Exp Biol. 51(10): 804–810.
- Bhushette Pravin R, Annapure Uday S (2017) Comparative study of *Acacia nilotica* exudate gum and acacia gum, International Journal of Biological Macromolecules 102: 266–271. <https://doi.org/10.1016/j.ijbiomac.2017.03.178>
- Dafallah AA, al-Mustafa Z (1996) Investigation of the anti-inflammatory activity of *Acacia nilotica* and *Hibiscus sabdariffa*. The American Journal of Chinese Medicine 24(3–4): 263–9. <https://doi.org/10.1142/S0192415X96000323>
- Fries RB, Wallace WA, Roy S, Kuppasamy P, Bergdall V, Gordillo GM, Melvin WS, Sen CK (2005) Dermal excisional wound healing in pigs following treatment with topically applied pure oxygen. Mutation Research/Fundamental and Molecular Mechanisms of Mutagenesis 579(1–2): 172–181. <https://doi.org/10.1016/j.mrfmmm.2005.02.023>
- Gupta A, Kumar P (2015) Assessment of the histological state of the healing wound. Plastic and Aesthetic Research 5: e15. <https://doi.org/10.4103/2347-9264.158862>
- Ibrahim N, Wong SK, Mohamed IN, Mohamed N, Chin KY, Ima-Nirwana S, Shuid AN (2018) Wound Healing Properties of Selected Natural Products. International Journal of Environmental Research and Public Health 15(11): e2360. <http://doi.org/10.3390/ijerph15112360>
- Kankara SS, Sani D, Mustafa M, Ibrahim MH, Go R (2017) *Acacia nilotica* pods' water extract enhances wound healing in SPRAGUE-DAWLEY rats by alleviating oxidative stress and suppressing pro-inflammatory cytokines, Nigerian Journal of Scientific Research 16(2). <https://doi.org/10.1016/j.bbrc.2015.12.042>
- Kilic N (2004) A Comparison between medetomidine-ketamine and xylazine-ketamine anaesthesia in rabbits. Turkish Journal of Veterinary and Animal Sciences 28: 921–926. <https://doi.org/10.1016/j.bbrc.2015.12.042>
- Lemo NG, Marignac E, Reyes-Gomez T, Lilin O, Crosaz DM, Emo NG, Ohan Ehrenfest (2010) Cutaneous reepithelialization and wound contraction after skin biopsies in rabbits: a mathematical model for healing and remodelling index. Vet. Arhiv. 80: 637–652. <https://doi.org/10.1016/j.bbrc.2015.12.042>
- López-Jornet P, Camacho-Alonso F, Molina-Miñano F, Vicente-Ortega V (2009) Effects of plasma rich in growth factors on wound healing of the tongue. Experimental study on rabbits. Medicina Oral Patología Oral y Cirugía Bucal. 14(9): e425–428.
- Malviya, SS, Rawat A, Kharia M, Verma SG and Shri B (2011) Medicinal attributes of *Acacia nilotica* Linn. – A comprehensive review on ethnopharmacological claims. Vol. 2(6): 830–837.
- Meena PD, Kaushik P, Shukla S, Soni AK, Kumar M, Kumar A (2006) Anticancer and antimutagenic properties of *Acacia nilotica* (Linn.) on 7,12-dimethylbenz(a)anthracene-induced skin papillomagenesis in Swiss albino mice. Asian Pacific Journal of Cancer Prevention 7(4): 627–632.
- Midwood KS, Williams LV, Schwarzbauer JE (2004) Tissue repair and the dynamics of the extracellular matrix. The International Journal of Biochemistry & Cell Biology 36(6): 1031–1037. <https://doi.org/10.1016/j.biocel.2003.12.003>
- Paknejad M, Rohn A, Eslami B, Afzalifar R, Safiri A (2017) Evaluation of Three Bone Substitute Materials in the Treatment of Experimentally Induced Defects in Rabbit Calvaria. Front Dent. 4(4): 171–176. <https://doi.org/10.1016/j.bbrc.2015.12.042>
- Phillips GO, Williams PA (2001) Tree exudates gums: Natural and versatile food additives and ingredients. Food Ingredients Analysis of International 23: 26–28. <https://doi.org/10.4236/fns.2011.29134>
- Pukki T, Tikkanen M, Halonen S (2010) Assessing Mepilex Border in Post-Operative Wound Care. Wounds-UK.
- Rajvaidhya S, Nagori BP, Singh GK, Dubey BK, Desai P, Alok S and Jain S (2012) A Review on *Acacia arabica* - An Indian Medicinal Plant. International Journal of Pharmaceutical Sciences and Research. 3(7): 1995–2005.
- Renard D, Lavenant-Gourgeon L, Ralet MC, Sanchez C (2006) Acacia Senegal gum: continuum of molecular species differing by their protein to sugar ratio, molecular weight, and charges. Biomacromolecules 11(7): 2637–2649. <https://doi.org/10.1021/bm060145j>
- Rodge AB, Sonkamble SM, Salve RV, Hashmi SI (2012) Effect of hydrocolloid (guar gum) incorporation on the quality characteristics of bread. Journal of Food Processing & Technology 13: e136. <https://doi.org/10.4172/2157-7110.1000136>
- Sharma AK, Kumar A, Kumar Yadav Sh, Rahal A (2014) “Studies on Antimicrobial and Immunomodulatory Effects of Hot Aqueous Extract of *Acacia nilotica* L. Leaves against Common Veterinary Pathogens”, Veterinary Medicine International 2014: 747042. <https://doi.org/10.1155/2014/747042>
- Suriyamoorthy S, Kalidass S, Wahaab F (2012) Evaluation of wound healing activity of *Acacia leucophloea* bark in rats, Rev. Bras. Farmacogn. Brazilian Journal of Pharmacognosy 22(6). <https://doi.org/10.1590/S0102-695X2012005000121>
- Takahashi K, Fukazawa M, Motohira H, Ochiai K, Nishikawa H, Miyata T (2003) A pilot study on antiplaque effects of mastic chewing gum in the oral cavity. Journal of Periodontology 74(4): 501–205. <https://doi.org/10.1902/jop.2003.74.4.501>
- Tangade PS, Mathur A, Tirth A, Kabasi S (2012) Anti-gingivitis effects of *Acacia arabica*-containing toothpaste. Chinese Journal of Dental Research 15(1): 49–53.
- Thakur R, Jain N, Pathak R, Sandhu SS (2011) Practices in Wound Healing Studies of Plants. Evidence-Based Complementary and Alternative Medicine. 1–17. <https://doi.org/10.1155/2011/438056>